

# Enterobius vermicularis in Immunocompromised Patients: A Case Report

SANGITHA JAYAGANDAN<sup>1</sup>, OUDHAYA KUMARAN<sup>2</sup>, NONIKA RAJKUMARI<sup>3</sup>

## ABSTRACT

One of the most prevalent nematode infections globally is *Enterobius vermicularis*, commonly known as pinworm. This infection is often seen among children living in poor socioeconomic conditions, in overcrowded households, and in immunocompromised patients with uncontrolled diabetes, hypertension, long-term steroid therapy, and other related issues. With treatment, the cure rate is between 90 to 95%. However, reinfection is frequent, particularly in cases where contacts are not treated concurrently. Hereby, the authors present a case report of two male patients (58 and 40 year-old) with uncontrolled diabetes mellitus who presented with pinworm infections in unconventional sites. *Enterobius vermicularis* can manifest in uncommon locations such as the caecum, the appendix, and other visceral organs of the abdomen, including the uterine endometrium. These atypical presentations can lead to more serious complications, such as granuloma and abscess formation, which may even result in infertility. Although pinworm infection is typically considered a childhood disease, immunosuppressed adults are also susceptible.

**Keywords:** Diabetes mellitus, Coronary artery disease, Granuloma, Pin worm

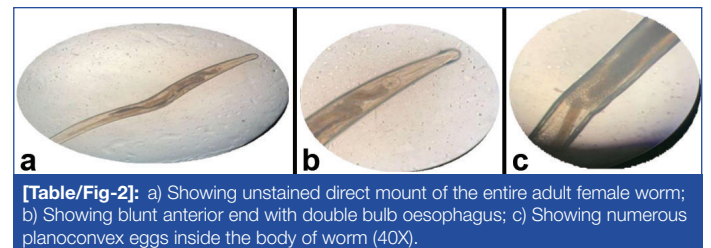
## CASE REPORT

### Case 1

A 58-year-old male, who is a farmer by occupation, reported to the Pulmonary Medicine Outpatient Department (OPD) with chief complaints of breathlessness, chest pain, and cough with expectoration lasting two days. He has a known history of diabetes and Coronary Artery Disease (CAD) and has been a known case of Obstructive Airway Disease (OAD) for 10 years, using inhalers intermittently during symptomatic episodes. The patient was intubated and mechanically ventilated due to respiratory distress in the Department of Pulmonary Medicine at hospital.

During his hospital stay, the patient developed pressure sores near the dorsal aspect of his right upper thigh, which subsequently ruptured and ulcerated [Table/Fig-1]. Upon examination of this lesion, the treating resident noticed thin, slender worms crawling near the lesion. Further, local examination revealed multiple thin, whitish worms crawling on the lesion and in the perianal region. The worms were collected using the cellophane tape method, and the slide was examined under a microscope. At 10x magnification, a

small, white, thread-like worm was observed. At 40x magnification, a thin, gravid female worm was noted, characterised by a double bulb oesophagus at the anterior end and a tapering, thin, straight pointed posterior end. The body of the worm was filled with planoconvex eggs, indicative of an adult female *Enterobius vermicularis*. All the collected worms displayed similar morphological features under the microscope [Table/Fig-2a-c].

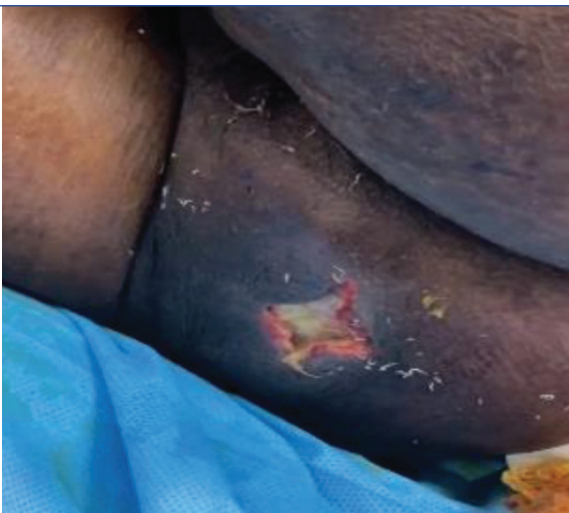

**[Table/Fig-2]:** a) Showing unstained direct mount of the entire adult female worm; b) Showing blunt anterior end with double bulb oesophagus; c) Showing numerous planoconvex eggs inside the body of worm (40X).

Repeat sampling was performed the next day, yielding worms with similar morphology. There was no reported history of parasitic infestations among his family members. An exudate sample from the abscess wound was sent for culture, which showed the growth of *Escherichia coli*. A Broncho-alveolar Lavage (BAL) sample was also sent for culture, revealing the growth of *Acinetobacter baumannii* and *Pseudomonas aeruginosa*. The patient was non-compliant with the anti-diabetic and anti-lipid medications prescribed for CAD, leading to uncontrolled blood sugar levels. Consequently, human insulin injections were initiated to control his diabetes, and oral aspirin and clopidogrel were added for CAD management. Inj. meropenem and oral minocycline were administered for the abscess wounds. Following the diagnosis of *Enterobius vermicularis*, the patient was given a stat dose of albendazole 400 mg, with a repeat dose scheduled for two weeks later.

### Case 2

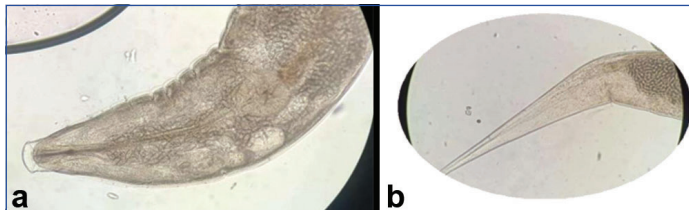
A 40-year-old male, known to be a type 2 diabetic for four years and currently on regular oral hypoglycaemic drugs, presented with pus discharge from the perianal region for a duration of two years and had recently started experiencing pain for the past two weeks. On local examination, a Fistula-in-ano was noted, with an external opening at the 5 o'clock position and an internal opening



**[Table/Fig-1]:** Showing *Enterobius vermicularis* worms crawling in and around the bed sore (case 1).

at approximately 3 o'clock, about 1 cm from the anal verge. Pus discharge was observed at the external opening.

Magnetic resonance fistulography was performed, which revealed a linear T2 hyperintense tract measuring 2.3 cm in length in the perianal region, with the external opening at the 6 o'clock position and the internal opening at the 4 o'clock position, 2.1 cm away from the anal verge. The fistulous tract was excised along its length, and during the procedure, a single parasitic worm was found embedded in the tract. The worm was collected and sent to the Department of Microbiology for identification. Under 40x magnification, a heavily gravid adult worm of *Enterobius vermicularis* was observed, characterised by a double bulb oesophagus and a body filled with planoconvex eggs [Table/Fig-3].



**[Table/Fig-3]:** a) Showing unstained direct mount of heavily gravid anterior end of adult female worm of *Enterobius vermicularis*. Numerous plano convex eggs can be seen inside body of the worm; b) Showing pointed posterior end of the worm (40X) (zoomed part).

Upon identification of the worm, the patient was given a single dose of albendazole 400 mg. The patient's postoperative period was uneventful, and he was discharged after 24 hours.

Histopathological examination of the excised fistulous tract showed fibromuscular and fibro-collagenous tissues, with a sinus tract lined by neutrophils, lymphocytes, and histiocytes, along with extensive crushing. No granuloma or atypical cells were observed. There was no history of parasitic infections noted in the family.

## DISCUSSION

*Enterobius vermicularis* has been successfully established as a parasite since the evolution of humans, and its infestations have become a health concern in developing and underdeveloped countries across all age groups [1,2]. Children aged 4-11 years are frequently affected, with a worldwide prevalence of 4 to 28%, occasionally showing a male predominance [2]. The eggs are infective upon release and are transmitted from person to person [1]. Close social contact, nail-biting, scratching of the perianal region, unsupervised personal hygiene practices, accidental anus-finger-mouth contact, and the habit of putting toys or inanimate objects in the mouth are some of the factors responsible for the higher infection rates in children [1,2].

Li HM et al., conducted a study in Guangdong province, China, involving five schools [3]. In present study, 802 children were examined, and 54% (440) were found to be infected with *Enterobius vermicularis*. Furthermore, it was noted that the lack of parental education and children's habits- such as not washing their hands before meals, after playing outside, and biting stationary items like pencils and pens while studying, as well as biting toys- played a significant role in acquiring the infection [3].

There is a risk of these parasites acting as opportunistic pathogens in immunocompromised adults and children due to waning or not fully developed immunity. Intestinal helminths, including *Ascaris lumbricoides*, *Enterobius vermicularis*, and *Strongyloides*, are known to infect immunocompromised patients [4]. In studies conducted by Abdel-Hafeez EH et al., and Rasti S et al., it was noted that *Strongyloides stercoralis* is frequently detected in immunocompromised individuals, while *E. vermicularis* and *A. lumbricoides* are considered non opportunistic, with no significant differences noted between immunocompromised and immunocompetent groups [5,6]. However, in 2018, Taghipour A et al., tested a group of immunocompromised individuals, including

patients suffering from tuberculosis, Human Immunodeficiency Virus (HIV), cancer, and transplant recipients. They noted that the prevalence of intestinal parasitic infections was around 34%, with the most prevalent being *Blastocystis* (18%) and the least prevalent being *E. vermicularis*, at around 2% [7].

Ambachew S et al., conducted a study in Northwest Ethiopia among diabetic patients. A total of 234 diabetic patients were enrolled in the study, of whom 19% were found to have intestinal parasitic infections. Among the participants with intestinal parasitic infections, 6% were infected with intestinal helminths such as *Ascaris lumbricoides*, *Schistosoma mansoni*, *Enterobius vermicularis*, and hookworms. Ambachew S et al., also noted that the prevalence of intestinal parasitic infections was twice as high in diabetic patients from rural populations compared to those from urban populations [8]. Although the reported numbers are low, we cannot dismiss the possibility of *Enterobius vermicularis* infection in patients with diabetes mellitus, as multiple studies have pointed out an increased prevalence of intestinal parasites in patients with uncontrolled diabetes, including pinworm infections. Additionally, most studies rely on stool microscopy. Since, *Enterobius vermicularis* is known to crawl and lay eggs around the perianal area, it is more likely to find eggs or worms in the perianal region, clothing, or bedding rather than in stool samples. Further, studies specifically targeting pinworm infections need to be conducted to conclude the association between *Enterobius vermicularis* infection and patients with uncontrolled diabetes mellitus.

*E. vermicularis* infection is often asymptomatic; when it does manifest, it typically presents as a nuisance with nocturnal itching that can lead to disturbed sleep, restlessness, and mechanical dermatitis of the perianal and vulvar areas [2,9]. However, heavy infestations of adult worms in the large intestine can lead to constipation, abdominal pain, tenesmus, and vaginitis. *E. vermicularis* has been found to be the cause of 7% of acute appendicitis cases [2]. Granuloma formation in the large intestine (caecum, sigmoid colon, and anal canal) and in extraintestinal sites such as the liver, lung, spleen, kidney, and bladder have been noted; rare cases of rectal malignancy have also been reported [1,2,10]. The perianal region is considered one of the rarest sites for the deposition of eggs, and intact skin acts as a barrier against *Enterobius* infections, as the worms cannot damage the skin [11,12]. On the contrary, it has also been suggested that *Enterobius* can navigate through healthy mucosa and the crypts of the anal canal [12].

Rajesh H et al., reported a case in 2019 of *Enterobius vermicularis* embedded in the uterine endometrium, leading to infertility [13]. The female worm can ascend to the peritoneum through the fallopian tube from the perianal area to the vagina. Pelvic peritoneal granulomas can also be caused by the worm if it manages to penetrate the intestinal wall. Such navigation by the larval and adult parasite can cause granulomata of the vulva, vagina, uterus, fallopian tubes, or ovaries, as well as salpingo-oophoritis, tubo-ovarian abscesses, and, in rare cases, destruction of the human embryo. They can pose as cervical and endometrial cancer, mimic the signs and symptoms of chronic inflammatory bowel disease, and have been shown to induce vulvovaginitis [1,13].

Diagnosis of *E. vermicularis* infection is made clinically and through direct visualisation of worms in the perianal area, in underwear, on bedsheets, and clothing, as well as by direct demonstration of eggs using the Scotch tape method or adult worms in stool samples. The sensitivity of the diagnostic test can be improved from 50 to 90% by increasing the sampling days to three [1]. Stool microscopy and serology are of little relevance. Despite their low worm load, mature worms can occasionally be seen during colonoscopy or proctoscopy when they present in atypical sites.

Since, the 1970s, pyrantel embonate, piperazine embonate, and mebendazole have been approved for treatment. These medications have eradication rates of over 90%. Mebendazole and albendazole

are the only two benzimidazole derivatives that are both ovicidal and adulticidal, making them the most effective medications available. Albendazole is expensive, hepatotoxic, and teratogenic. However, with only 7% of the drug being absorbed into systemic circulation, it concentrates more in the large intestinal lumen, making it a better candidate for the treatment of pure intestinal enterobiasis. Repeat administration can be done after 14 days and 28 days to prevent reinfection due to autoinfection, and all household contacts, including asymptomatic individuals, need to be treated [1].

## CONCLUSION(S)

*Enterobius vermicularis* is primarily a paediatric illness because young children often do not yet understand the importance of hygiene and self-care, and their developing immune systems are not fully capable of fending off many infections. However, *Enterobius vermicularis* can occasionally infect immunocompromised or weakened adults, which emphasises the importance of routine screening for this population. Conversely, while *Enterobius vermicularis* typically presents in healthy individuals with classic symptoms, it can also appear in unexpected anatomical locations, which calls for heightened suspicion.

## REFERENCES

- [1] Wendt S, Trawinski H, Schubert S, Rodloff AC, Mössner J, Lübbert C. The diagnosis and treatment of pinworm infection. *DtschArzteblatt Int*. 2019;116(13):213-19.
- [2] Khayyat R, BelkebirS, Abuseir S, Barahmeh M, Alsadder L, Basha W. Prevalence of and risk factors for *Enterobiusvermicularis* infestation in preschool children, West Bank, Palestine, 2015. *East Mediterr Health J Rev SanteMediterr Orient Al-Majallah Al- Sihhiyah Li-Sharq Al-Mutawassit*. 2021;27(11):1052-60.
- [3] Li HM, Zhou CH, Li ZS, Deng ZH, Ruan CW, Zhang QM, et al. Risk factors for *Enterobiusvermicularis* infection in children in Gaozhou, Guangdong, China. *Infect Dis Poverty*. 2015;4(1):28.
- [4] Al-Yousofi A, Yan Y, Al\_Mekhlafi AM, Hezam K, Abouelnazar FA, Al-Rateb B, et al. Prevalence of intestinal parasites among immunocompromised patients, children, and adults in Sana'a, Yemen. *J Trop Med [Internet]*. 2022 [cited 2023 Dec 28];2022. Available from: <https://www.ncbi.nlm.nih.gov/pmc/articles/PMC9200594/>.
- [5] Abdel-Hafeez EH, Ahmad AK, Ali BA, Moslam FA. Opportunistic Parasites among Immunosuppressed Children in Minia District, Egypt. *Korean J Parasitol*. 2012;50(1):57-62.
- [6] Rasti S, Hassanzadeh M, Hooshyar H, Momen-Heravi M, Mousavi SGA, Abdoli A. Intestinal parasitic infections in different groups of immunocompromised patients in Kashan and Qom cities, central Iran. *Scand J Gastroenterol*. 2017 Jun-Jul;52(6-7):738-41.
- [7] Taghipour A, Azimi T, Javanmard E, Pormohammad A, Olfatifar M, Rostami A, et al. Immunocompromised patients with pulmonary tuberculosis; a susceptible group to intestinal parasites. *Gastroenterol Hepatol Bed Bench*. 2018;11(Suppl 1):S134-39.
- [8] Ambachew S, Assefa M, Tegegne Y, Zeleke AJ. The prevalence of intestinal parasites and their associated factors among diabetes mellitus patients at the university of gondar referral Hospital, Northwest Ethiopia. *J Parasitol Res*. 2020;2020:8855965.
- [9] Fantinatti M, Da-CruzAM. *Enterobiusvermicularis* in Brazil: An integrative review. *Rev Soc Bras Med Trop*. 2023;56:e00732023.
- [10] Mendosa A, Mathison BA, Pritt BS, Lamps LW, Pai SA. Intramural Ova of *Enterobiusvermicularis* in the Appendix-An Egg-Topic Location! *Int J Surg Pathol*. 2022;30(2):214-16.
- [11] Khubchandani IT, Bub DS. Parasitic Infections. *Clin Colon Rectal Surg*. 2019;32(5):364-71.
- [12] Gupta B, Jain S. Perianal nodule due to *Enterobiusvermicularis*: Cytomorphological spectrum on fine needle aspiration cytology with a review of literature. *Trop Parasitol*. 2018;8(1):53-55.
- [13] Rajesh H, Kuppusamy B, Venkataswamy C, Ganesan N. *Enterobiusvermicularis* Infection of the Uterine Endometrium in an Infertile Female. *J Obstet Gynaecol India*. 2020;70(1):89-91.

### PARTICULARS OF CONTRIBUTORS:

1. Senior Resident, Department of Microbiology, JIPMER, Puducherry, India.
2. Junior Resident, Department of Microbiology, JIPMER, Puducherry, India.
3. Additional Professor, Department of Microbiology, JIPMER, Puducherry, India.

### NAME, ADDRESS, E-MAIL ID OF THE CORRESPONDING AUTHOR:

Dr. Nonika Rajkumari,  
Additional Professor, Department of Microbiology, JIPMER, Dhanvantri Nagar,  
Puducherry-605006, India.  
E-mail: nonika.raj@gmail.com

### AUTHOR DECLARATION:

- Financial or Other Competing Interests: None
- Was informed consent obtained from the subjects involved in the study? Yes
- For any images presented appropriate consent has been obtained from the subjects. Yes

### PLAGIARISM CHECKING METHODS: [Jain H et al.]

- Plagiarism X-checker: Mar 11, 2024
- Manual Googling: May 11, 2024
- iThenticate Software: Sep 27, 2024 (8%)

### ETYMOLOGY: Author Origin

EMENDATIONS: 6

Date of Submission: **Mar 09, 2024**  
Date of Peer Review: **May 08, 2024**  
Date of Acceptance: **Sep 28, 2024**  
Date of Publishing: **Nov 01, 2024**